

New developments in CT scanning for implant dentistry

Stephen E B Jones BDS, MSc, MGDS, MRD

Dr Stephen Jones examines the use of CT scanning and discusses its advantages



Figure 1a: Part of DPT (with radiopaque markers)

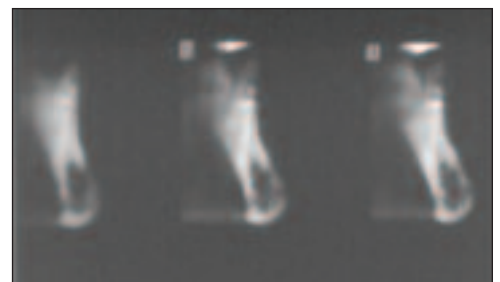


Figure 1b: Conventional tomograms of limited diagnostic value

Stephen Jones and his Partner, Rob Oretti, operate a referral centre for Reconstructive Dentistry and Cone Beam CT Imaging in Newbury, Berkshire.

Computerised Tomography (CT) was developed in the 1970s for medical use as a way to view hard tissues in cross section. Though largely superseded in medicine by Magnetic Resonance Imaging (MRI) CT imaging is now far less costly. It is also ideally suited to diagnostic work in dental implant treatment, where the volume of hard tissue available is often critical to the advisability, cost and planning of any treatment. Recently cone beam computed tomography (CBCT) scanners have been developed. Their compact size and relatively low radiation dose make them ideally suited for imaging the craniofacial region in dental practices.

The following questions need to be asked when considering the benefits of a CT scan for a patient planning to undergo dental implant treatment. When might a patient benefit

from CT scanning? Will the scan give the correct measurements of the hard tissues? Can the radiation dosage be justified? Are there benefits in carrying out computer-guided surgery? Lastly the cost and inconvenience of travelling to the CT scanning centre may need to be considered.

CT scanning became well established as a diagnostic aid in the 1980s. Practitioners were able to view reformatted views of the jaws for the first time (Schwarz et al, 1987, Andersson and Svartz, 1988). The technique was quickly established in Sweden and a subsequent paper (Ekkestubbe et al, 1997) showed a far higher usage of CT than in other parts of the world. The main reason for this was a high scanner-to-population ratio since Sweden had a highly developed health system. Techniques such as ridge-mapping

can only be used in superficial areas in mapping the dimensions of the jaws and even in the anterior maxilla, a critical region for implant placement, it has been seen to be unreliable (Allen and Smith, 2000). Conventional tomography is known to produce distorted images because often only part of the jaws is actually in focus (Reddy et al, 1994, Hanazawa et al, 2004). An example featuring the posterior mandible is shown below. The purpose of the radiographic investigations was to establish the dimensions of the mandible, the position of the inferior dental nerve canal and the emergence of the mental nerve, prior to implant surgery.

The anatomical areas in the maxilla where CT scanning provides far more accurate diagnostic information is in the topography of the floor of the nose, maxillary sinuses and the incisal

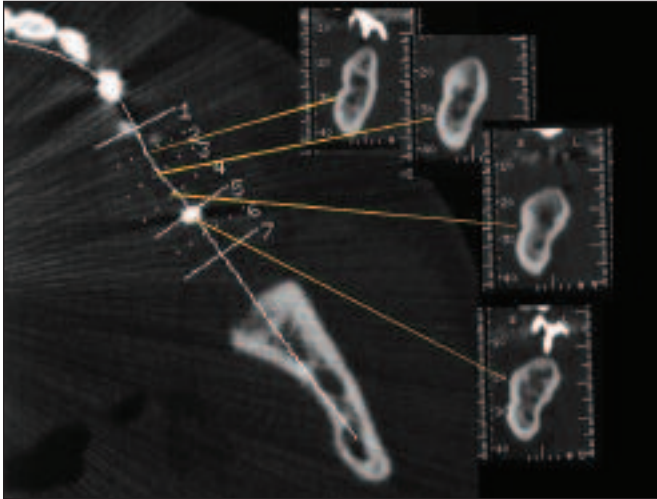


Figure 2: Views of reformatted slices clearly showing relevant anatomy

canal. The use of barium coating or incorporation of barium into acrylic teeth were positioned used in the CT scanning process to allow the clinician to plan the path of insertion of the dental implants (as above). The radiopaque positioning device then became the stent used during the implant treatment (Basten and Kois, 1996).

Initially the cost of CT scanners limited them to hospitals. An early concern was the radiographic dose of the CT scans. There has never been any disputing that all doses are higher for CT scans over conventional tomography (DPTs). However

the dose will vary depending on the scanner used, its kV, the number of slices and the Volume of Interest (VOI) actually scanned (Ekestubbe et al, 1993). Likewise the dose from conventional tomography has changed over the years through more sensitive intensifying screens used in the film cassettes and latterly with digital sensor and phosphor plate technology.

Cone beam computed tomography (CBCT) scanners were first produced in 1999. All these CBCT machines use a cone-shaped x-ray beam rather than a conventional linear fan beam.

They use a square two dimensional array of detectors to capture the cone shaped beam. This captures a 'volume of data' and subsequent reconstruction software manipulates this volumetric data to produce a stack of gray scale level images of the craniofacial anatomy.

Recently three papers (Ludlow et al, 2003, Tsiklakis et al, 2005, Ludlow et al, 2006) have looked at comparing the dosimetry of the new cone beam CBCT machines with panoramic tomography, and with each other. These machines are all designed for installation in dental practices but at present are several times more expensive than digital DPT machines. The NewTom 3G was compared

with a Orthophos Plus DS DPT machine (Ludlow et al, 2003) and the whole-body effective scan dose of between 36 and 41 mSv was significantly greater than the DPT dose of between 6 and 22 mSv. Therefore the NewTom CT was between two and four times the DPT radiation dose. However this should be compared with the effective whole-body dose for a conventional hospital CT that is over 300 mSv. A further paper (Tsiklakis et al, 2005) showed further reduction of the whole-body dose by wearing of a lead apron during the scanning process, and specially drew attention to the desirability of limiting the radiation dose to the thyroid.

A study comparing the dosages of the CB Mercury, i-CAT and NewTom 3G reproduced the relatively low 40-50 mSv dose of the NewTom 3G, a 135-190 mSv dose for the i-CAT and a dose of 480-560 mSv for the CB Mercury machine. The authors noted that these were 4 to 42 times the dose of a comparable DPT but it should be noted that these were using 30cm scanning volumes i.e. whole height of skull, which are far in excess of those that can be used routinely in dental implant-related work.

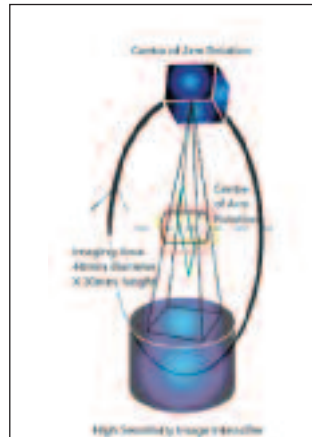


Figure 3: Mechanics of a cone beam scanner



Figure 4: Several new cone beam CT scanners now on the market

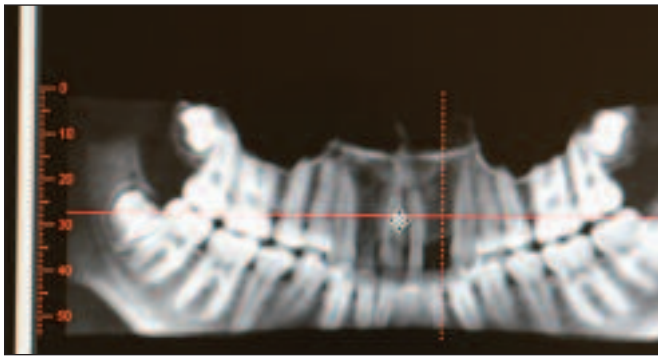
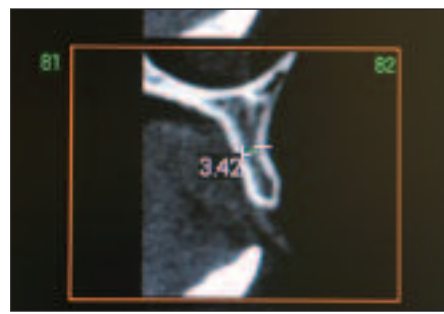
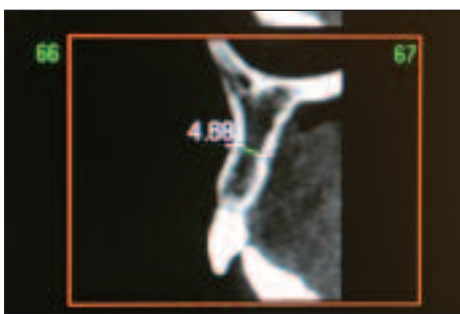

Figure 5: 6cm Volumetric data (scanned with i-CAT)



Figures 6a and b: Reformatted slices clearly show adequate width for implants at 12, but probably not at the 22 site

It is always accepted that the need to keep radiation dosage 'as low as reasonably achievable' in young patients may preclude them from CT scanning. However the following case study shows a carefully limited scan (i-CAT with scan volume of only 6cm) of a 16-year-old girl missing both lateral incisors. The upper right deciduous lateral incisor is still present.

This information could not have been gained with sufficient accuracy by ridge-mapping and since the volume of interest was restricted to 6cm the whole-body radiation dose might be as little as 40mSv, or two conventional DPTs. This degree of dose, which is common via DPTs during orthodontic treatment in even younger children, might well now be justified.

The following case study is of a posterior implant site in a heavily built man aged 72. The

panoramic view derived from the i-CAT scan shows a deep body of mandible nearly 3cm in depth. The inferior dental canal is in its usual position, a few millimetres above the lower border of the mandible and there appears to be up to 20mm depth in which to place implants.

This is clearly a case where placing a longer implant in a vertical direction might have led to perforation of the lingual cortical plate and collateral damage. In the event a wide-bodied 10mm length implant was safely placed at this site. This case leads neatly on to the subject of assessment of bone quality or density from the CT scan alone, and then on to the use of navigation-guided, or computer-guided drilling techniques. Several papers (Norton and Gamble, 2001, Beer et al, 2003, Todisco and Trisi, 2005, Ikumi and Tsutsumi, 2005) have con-

cluded that carefully calibrated software examining reformatted CT can predict the density of bone prior to preparing an implant site. This may help the surgeon to decide upon any one of several preparation techniques for particularly hard or soft bone prior to surgery and, in addition, it may well also influence the selection of implant. This has not become as widespread as the publicity surrounding what has become known as navigated, or computer-guided, implant placement.

Several papers (Gaggl et al, 2001, Hoffman et al, 2005, Rosenfeld et al, 2006) have shown that navigation devices, usually acrylic stents made to fit to a hard tissue base with metal tube apertures for drills of preset widths and lengths, prepare implant sites very accurately from CT data. It would not be expected that these devices con-

structed from cone beam CT data would be any less accurate. Certainly they will be far more accurate than the traditional acrylic stents (Basten and Kois, 1996). However these guided systems will tend to be ideal in the 'easier' cases, where bone is relatively plentiful, and they cannot contribute very much to cases where preliminary bone grafting is required. Several software companies (3D-Diagnostix, Simplant, CAD Implant, DENX, Medical Modelling, iDent for example) can provide accessory tools to allow planning of the case, superimposition of virtual implants, highlighting of various anatomical structures. These can be used to make stereo lithographic models of the jaws and/or navigational guide stents. One study (Gaggl et al, 2001) noted that though the precision of the guided navigation drilling was high there

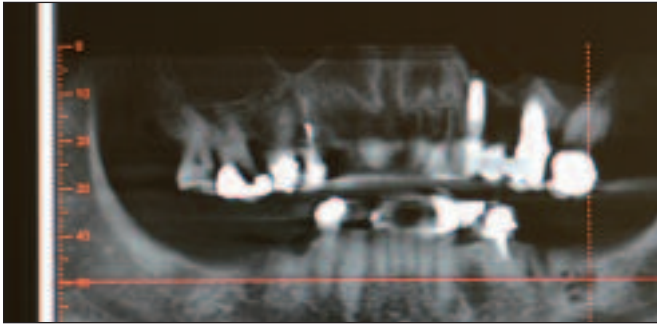


Figure 7: A panoramic view derived from the i-CAT scan

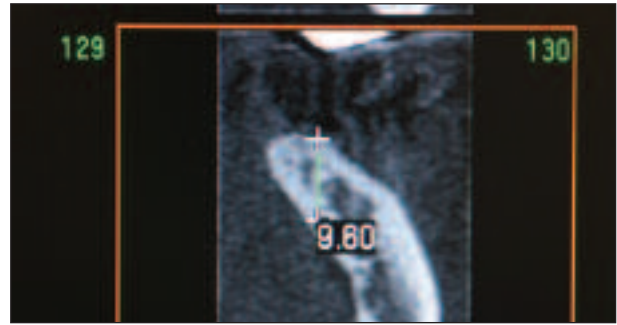


Figure 8: A reformatted slice shows less than 10mm of vertical space for an implant

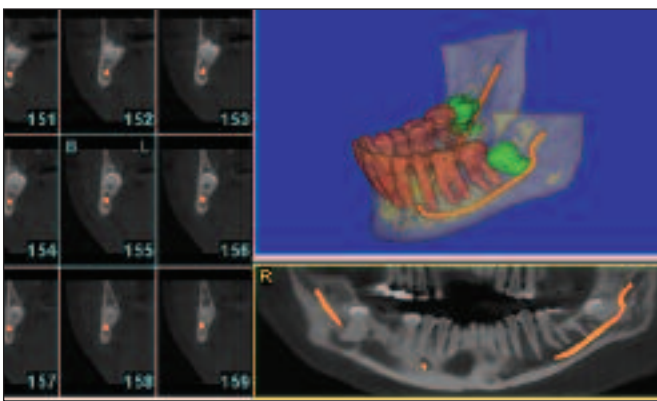


Figure 9: Example of 'embellishment' software

was a high incidence of penetrations into the maxillary sinus by subsequent implant placement.

Both the software and all the associated paraphernalia that needs to be assembled to proceed with these procedures is expensive and it is always necessary to assess the cost-effectiveness of this new technology. It should be remembered that bone, especially in the maxilla, is often soft and malleable. Lifting and expanding of the bony structures cannot be easily 'simulated'. To carry out these procedures the implant surgeon must test the bony resistance at surgery.

We should remember that the huge original advantage of CT, namely the provision of accurate reformatted views of craniofacial

hard structures, are what we fundamentally require. In 2000 The American Association of Oral and Maxillofacial Radiologists released a position statement stating 'It is recommended that some form of cross-sectional imaging be used for implant cases and that the conventional cross-sectional tomography be the method of choice.' (Tyndall and Brooks, 2000) The reduction in dose with CBCT and the ability to further limit the volume of data, together with the relative ease of use in a dental practice, challenges this statement.

It is also virtually certain that the cost of a CT scan in a dental practice environment will be far less than that of a CT scan at a hospital. In addition, these

machines will also have a part to play in assessing patients for a wide variety of orthodontic, TMJ, and oral surgery procedures, as well as in dental implant treatment.

References

Schwarz M, Rothman S, Chafetz N, Rhodes M. Computerized tomography. Part 1. Preoperative assessment of the mandible for endosseous implant surgery. *Int J Oral Maxillofac Implants.* 1987;2:137-141

Andersson JE, Svartz K. CT-scanning in the preoperative planning of osseointegrated implants in the maxilla. *Int J Oral Maxillofac Surg.* 1988;17:33-5.

Ekestubbe A, Grondahl K, Grondahl HG. The use of tomography for dental implant planning. *1997;26:206-13.*

Allen F, Smith DG. An assessment of the accuracy of ridge-mapping in planning implant therapy for the anterior maxilla. *Clin Oral Implants Res.* 2000;11:34-8.

Reddy MS et al. A comparison of the diagnostic advantages of panoramic radiography and computed tomography scanning for placement of root form dental implants. *Clin Oral Implants Res.* 1994;5:229-38.

Hanazawa T, Sano T, Seki K, Okano T. Radiologic measurements of the mandible: a comparison between CT-reformatted and

conventional tomographic images. *Clin Oral Implants Res.* 2004;15:226-32

Basten C, Kois J. The use of barium sulfate for implant templates. *J Prosthet Dent* 1996;76:451-454.

Ekestubbe A, Thilander A, Grondahl K & Grondahl HG. Absorbed doses from computed tomography for dental implant surgery: comparison with conventional tomography. *Dentomaxillofac Radiol.* 1993;22:13-17

Ludlow JB, Davis-Ludlow LE, Brooks SL. Dosimetry of two extraoral direct digital imaging devices: NewTom cone beam CT and Orthophos Plus DS panoramic unit. *Dentomaxillofac Radiol.* 2003;32:229-34

Tsiklakis K et al. Dose reduction in maxillofacial imaging using low dose Cone Beam CT. *Eur J Radiol.* 2005;56:413-7

Ludlow JB et al. Dosimetry of 3 CBCT devices for oral and maxillofacial radiology: CB Mercuray, NewTom 3G and i-CAT. *Dentomaxillofac Radiol.* 2006;35:219-26

Norton MR, Gamble C. Bone classification: an objective scale of bone density using the computerized tomography scan. *Clin Oral Implants Res.* 2001;12:79-84

Beer A et al. Correlation of insertion torques with bone mineral density from quantitative CT in the mandible. *Clin Oral Implants Res.* 2003;14:616-20

Todisco M, Trisi P. Bone mineral density and bone histomorphometry are statistically related. *Int J Maxillofac Implants.* 2005;20:898-904

Ikumi N, Tsutsumi S. Assessment of correlation between computerized tomography values of the bone and cutting torque values at implant placement: a clinical study. *Int J Maxillofac Implants.* 2005;20:253-60

Gaggl A, Schultes G, Karcher H. Navigational precision of drilling tools preventing damage to the mandibular canal. *J Craniomaxillofac Surg.* 2001;29:271-5

Hoffman J, Westendorff C, Schneider M, Reinert S. Accuracy of image guided implant surgery: an experimental study. *Int J Maxillofac Implants.* 2005;20:382-6

Hoffman J, Westendorff C, Gomez-Roman G, Reinert S. Accuracy of navigation-guided socket drilling before implant installation compared to the conventional free-hand method in a synthetic edentulous lower jaw model. *Clin Oral Implants Res.* 2005;16:609-14

Rosenfeld AL, Madelaris GA, Tardieu PB. Prosthetically directed implant placement using computer software to ensure precise placement and predictable prosthetic outcomes Part I: diagnostics, imaging, and collaborative accountability. *Int J Periodontics Restorative Dent.* 2006;26:215-21.

Tyndall A, Brooks S. Selection criteria for dental implant site imaging. A position paper of the American Academy of Oral and Maxillofacial Radiology. *Oral Surg Oral Med Oral Pathol Oral Radiol Endod* 2000;89:630-637

CPD

This article is equivalent to one hour of verifiable CPD. To receive credit, complete the five-question test and return by post, fax or email to the addresses on the right:

A&ID Verifiable CPD,
 FMC Ltd
 1 Hertford House,
 Shenley, WD7 9BR
 Fax: 01923 851778
Debbie.Levy@fmc.co.uk

REF: A&ID/XXX06/XXXX

Name: _____
 Subscriber no.: _____
 GDC registration no.: _____
 Address: _____

 Tel: _____

Q1 GGGGGGGG

- a)
- b)
- c)
- d)
- e)

Q2 GGGGGGGGGGGGGG

- a) ggggg
- b) gggggg
- c) ggggggg

Q3 gggggggggggg

- a) Vggggggg
- b) ffffffff
- c) Vfffffff

Q4 ffffffff

gggggggggggggg

- a) ffffffff
- b) ffffffff
- c) ffffffff
- d) ffffffff
- d) ffffffff

Q5 ffff

ffff rfff

- a) fffff
- b) fffff
- c) fffff
- d) fffff